

**12**

**AUTOPSY REPORT**

No. 2022-11542

CARTER, AARON CHARLES

I performed an autopsy on the body of →

at \_\_\_\_\_ the DEPARTMENT OF MEDICAL EXAMINER-CORONER

Los Angeles, California on November 6, 2022 at 0940  
(Date) (Time)

From the anatomic findings and pertinent history I ascribe the death to:

(A) DROWNING

DUE TO OR AS A CONSEQUENCE OF

(B) EFFECTS OF DIFLUOROETHANE AND ALPRAZOLAM

DUE TO OR AS A CONSEQUENCE OF

(C)

DUE TO OR AS A CONSEQUENCE OF

(D)

OTHER CONDITIONS CONTRIBUTING BUT NOT RELATED TO THE IMMEDIATE CAUSE OF DEATH

MANNER OF DEATH

ACCIDENT

HOW INJURY OCCURRED

SUBMERGED IN BATHTUB AFTER INHALATION OF COMPRESSED GAS AND INTAKE OF ALPRAZOLAM

**Anatomic Summary :**

- I. Pulmonary edema and congestion
  - A. Right lung: 900 grams
  - B. Left lung: 850 grams

II. No life-threatening traumatic injuries

**CIRCUMSTANCES :**

According to investigative reports this 34-year-old male was found submerged under water and unresponsive in his bathtub. Medics responded and pronounced death at the scene. Please see Coroner Investigator's report for further information.

**EXTERNAL EXAMINATION :**

The body is identified by toe tags and is that of an unembalmed refrigerated adult male who appears the reported age of 34 years. The body measures 69 inches, weighs 133 pounds, and is normally developed. The body habitus is thin. Examination of the skin shows no jaundice. No prominent scars are identified.

There are numerous tattoos including:

- Butterfly on right forehead
- "Prince" under the right eye
- "Karma" above the left eye

**12****AUTOPSY REPORT**

No. 2022-11542

CARTER, AARON CHARLES

Page 2

- A Medusa head on the left face
- A lion head on the right neck
- A microphone on the right chest
- A piano on the left chest
- A microphone on the anterior right forearm
- Flowers on the posterior right forearm
- A cross, compass, and doves on the anterior left forearm
- Piano keys on the posterior left forearm
- A sun design on the upper mid back

The scalp hair is blond/brown and appears bleached. The facial hair is shaven. Examination of the eyes reveals brown irides and sclerae that are white. The conjunctivae are not congested. The oronasal passages are unobstructed. The upper and lower teeth are incomplete. Frenulae and oral mucosa are intact. No petechial hemorrhages are identified.

There is no chest deformity. There is no increased anterior-posterior diameter. The abdomen is not distended. The genitalia are those of an adult male. The external genitalia are unremarkable. The extremities show no edema or joint deformity.

**EVIDENCE OF THERAPEUTIC INTERVENTION:**

There is no evidence of therapeutic intervention. There has not been postmortem intervention for organ or tissue procurement.

**POSTMORTEM CHANGES:**

Rigor mortis is present. Livor mortis is minimal and in a predominately posterior distribution. It blanches with firm pressure.

**EVIDENCE OF NON-FATAL INJURY:**

There is 1/8 inch abrasion on the superior aspect of the philtrum of the upper lip just below the base of the nasal septum.

There is a 1/4 inch subungual hematoma in the nail bed of the right index finger.

**12****AUTOPSY REPORT**

No. 2022-11542

CARTER, AARON CHARLES

Page 3**INITIAL INCISION:**

The body cavities are entered through the standard coronal incision and the standard Y-shaped incision.

**NECK:**

The neck organs are removed en bloc with the tongue. No foreign material is present in the mouth, upper airway, or trachea. There is no edema of the larynx. Both the hyoid bone and the larynx are intact and without fractures. No hemorrhage is present in the adjacent throat organs, investing fascia, strap muscles, thyroid, or visceral fascia. There are no prevertebral fascial hemorrhages. The tongue when sectioned shows no trauma.

**CHEST/ABDOMINAL CAVITY:**

No pleural effusions are present. Pleural adhesions are not present. The organs of the abdominal cavity have a normal arrangement and none are absent. Ascites is not present. The peritoneal cavity is without evidence of peritonitis. There are no abdominal adhesions.

**SYSTEMIC AND ORGAN REVIEW:**

Note: The following observations are limited to findings other than described above.

**MUSCULOSKELETAL SYSTEM:**

No abnormalities of the bony framework or muscles are identified.

**CARDIOVASCULAR SYSTEM:**

The thoracic and abdominal aorta have minimal atherosclerosis. There is no tortuosity or widening of the thoracic segment. There is no dilation of the lower abdominal segment. No aneurysm is present. The major branches of the aorta show no abnormality. The pericardial sac contains scant serous fluid.

The heart weighs 340 grams. It has a normal configuration. The heart shape is not globular and the myocardium is not flabby. The right ventricle is 0.2 cm, the interventricular septum is 1.1 cm, and the left ventricle is 1.2 cm in thickness. The chambers are normally developed and are without mural thrombosis. The valves are thin, leafy, and appear competent.

**12****AUTOPSY REPORT**

No. 2022-11542

CARTER, AARON CHARLES

Page 4

No cardiac valve vegetations are present. There is no abnormality of the apices of the papillary musculature. There are no defects of the septum. The great vessels enter and leave in a normal fashion.

The coronary ostia are patent, located at or below the sinotubular junction, and are centrally located within their respective sinuses. The coronary artery distribution is right dominant. Serial sectioning of the coronary arteries shows widely patent lumina in all the major segments and no significant atherosclerotic stenosis.

**RESPIRATORY SYSTEM:**

Scant secretions are found in the upper respiratory and lower bronchial passages. The right lung is 900 grams and the left lung is 850 grams. The pulmonary parenchyma is dark red-purple and the cut surfaces exude a large amount of frothy fluid. The visceral pleurae are unremarkable. The pulmonary vasculature is without thromboembolism.

**GASTROINTESTINAL SYSTEM:**

The esophagus is intact throughout. Esophageal varices are not present. The stomach contains approximately 325 cc of green-yellow liquid with fine, white, chalky particulate. The mucosa is unremarkable. The small intestine and colon are unremarkable. They contain non-formed stool. The appendix is unremarkable. There is no necrosis, hemorrhage or fibrosis of the pancreas.

**HEPATOBIILIARY SYSTEM:**

The liver is 1850 grams and is brown-red. The capsule is intact and the consistency of the parenchyma is semifirm. The cut surface is smooth and homogeneous. There is no evidence of cirrhosis. The gallbladder is present. The wall is thin and pliable. It contains a moderate amount of bile and no calculi.

**URINARY SYSTEM:**

The right kidney is 150 grams. The left kidney is 140 grams. The kidneys are normally situated and the capsules strip easily revealing a surface that is smooth and glistening. The corticomedullary demarcation is preserved. The pyramids are not remarkable. The ureters are without dilation or obstruction and

**12****AUTOPSY REPORT**

No. 2022-11542

CARTER, AARON CHARLES

Page 5

pursue their normal course. The urinary bladder is unremarkable. It contains approximately 10 cc of urine.

**GENITAL SYSTEM:**

The prostate is not enlarged and is without nodularity. Both testes are in the scrotum and are unremarkable.

**HEMOLYMPHATIC SYSTEM:**

The spleen is 115 grams. The capsule is intact. The parenchyma is dark red and soft. The bone marrow of the ribs is unremarkable.

**ENDOCRINE SYSTEM:**

The thyroid, adrenal, and pituitary glands are unremarkable. The parathyroid glands are not individually dissected. The thymus is the usual appearance for the age.

**SPECIAL SENSES:**

The eyes are not dissected. The middle and inner ear are not dissected.

**HEAD AND CENTRAL NERVOUS SYSTEM:**

There is no subcutaneous hemorrhage within the scalp. The external periosteum is unremarkable. The dura mater is unremarkable. There is no epidural, subdural or subarachnoid hemorrhage. The dura mater is stripped showing no fractures of the calvarium or base of the skull. There is notable red congestion within the mastoid air cells bilaterally.

The brain weighs 1510 grams. The leptomeninges are thin and transparent. A mildly flatten convolutionary pattern is observed. The brain is diffusely softened. Pons, medulla, and cerebellum are unremarkable. There is no evidence of uncal or cerebellar herniation. Vessels at the base of the brain have a normal pattern of distribution. There are no aneurysms. The cerebral arteries show minimal atherosclerosis.

Coronal sectioning demonstrates a uniformity of cortical gray thickness. The basal ganglia are intact. Anatomic landmarks are preserved. Cerebral contusions are not present. The ventricular system has a normal appearance without dilation or distortion. There is no intraparenchymal hemorrhage.

**12****AUTOPSY REPORT**

No. 2022-11542

CARTER, AARON CHARLES

Page 6**SPINAL CORD:**

The cervical cord is examined through the foramen magnum and is grossly unremarkable.

**EVIDENCE COLLECTION:**

None.

**RETAINED TISSUE:**

Representative sections from various organs are preserved in one storage jar.

**HISTOLOGIC KEY:**

None.

**TOXICOLOGY:**

Samples of heart blood, femoral blood, liver, gastric contents, urine, and vitreous are submitted to the laboratory. An EDTA tube of heart blood is collected as a typing specimen.

**SPECIAL PROCEDURES:**

None.

**PHOTOGRAPHY:**

No photographs were taken during the course of the autopsy.

**RADIOLOGY:**

No postmortem radiologic examination was performed.

**WITNESSES:**

There were no outside personnel present to witness the autopsy.

**DIAGRAMS USED:**

Diagram form #20 was used during the performance of the autopsy. Medical examiner diagrams are not intended to be facsimiles nor are they drawn to scale.



**12****AUTOPSY REPORT**

No. 2022-11542

CARTER, AARON CHARLES

Page 7**SUMMARY & OPINION:**

This 34-year-old male, Aaron Carter, was found submerged under water and unresponsive in his bathtub. Medics responded and pronounced death at the scene.

Autopsy revealed marked pulmonary edema and no fatal trauma.

Toxicological testing detected the presence of difluoroethane and alprazolam in Mr. Carter's system. Additionally, anti-histamine and quetiapine metabolites were present.

Difluoroethane is a gas commonly used as a propellant in air spray cleaners for electronic devices that can induce feelings of euphoria when inhaled. It is known to have cardiotoxic effects which can lead to cardiac arrhythmias and sudden cardiac arrest. Alprazolam (a benzodiazepine) has depressant effects on the central nervous system which can cause drowsiness and sedation.

Based on the autopsy findings, investigative reports and circumstances, as currently known, Mr. Carter became incapacitated while in the bathtub due to the effects of inhaling compressed gas and taking alprazolam. This resulted in him becoming submerged under water, unable to breath, and ultimately led to his death.

The cause of death is drowning due to the effects of difluoroethane and alprazolam. The manner of death is accident.

B. Hunt

Brice L. Hunt, M.D.  
Interim Senior Deputy Medical Examiner

4-14-2023

Date

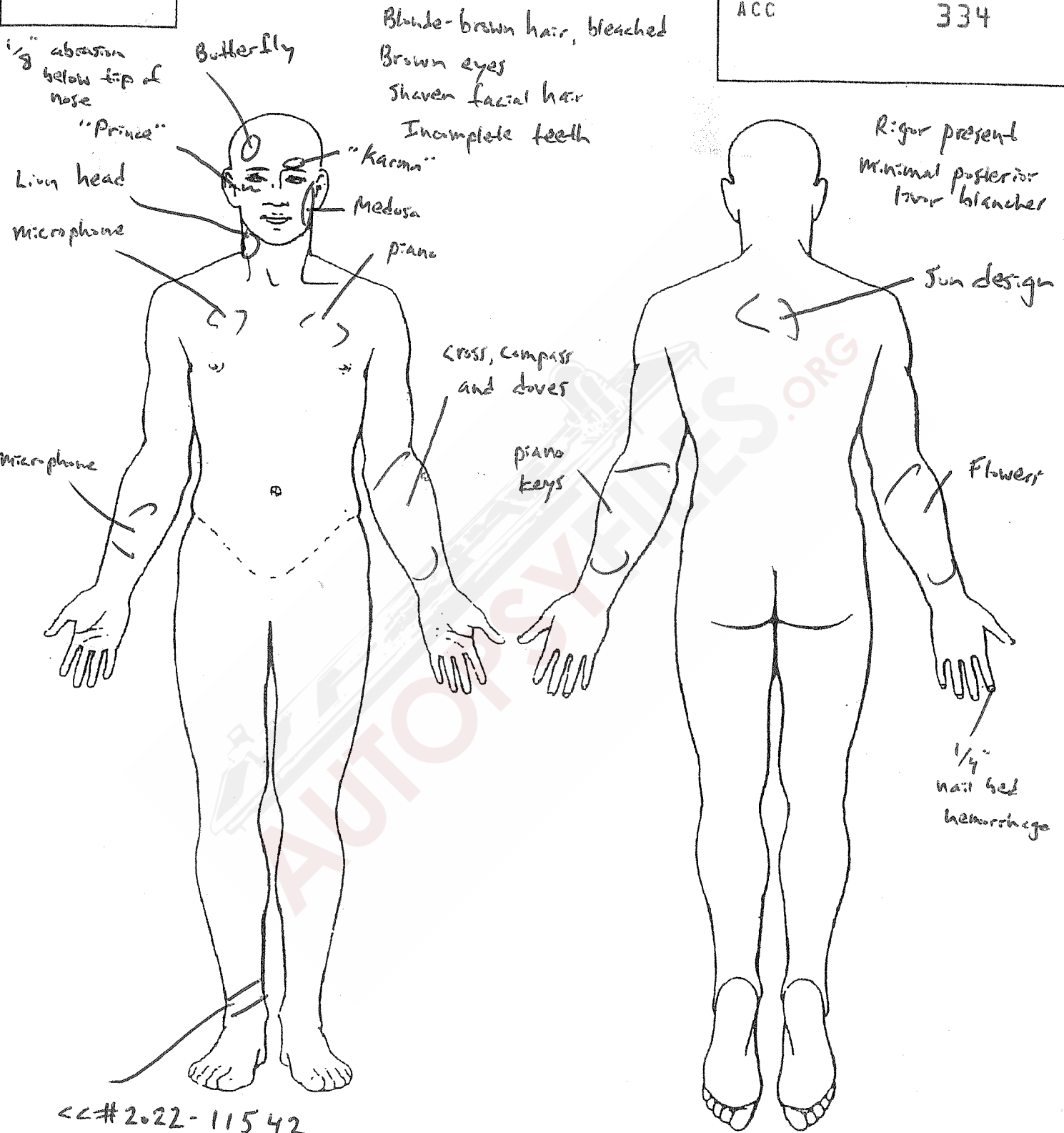
20

2022-11542

CARTER, AARON CHARLES

ACC

334



Date 11-6-2022

0940

73716

M.D.

Deputy Medical Examiner



# 16

2022-11542

CARTER, AARON CHARLES  
ACC 334

**EXTERNAL EXAM**

Sex *Male*  
Race  
Age *34*  
Height *69*  
Weight *133*  
Hair  
Eyes  
Sclera  
Teeth  
Mouth  
Tongue  
Nose  
Chest  
Breasts  
Abdomen  
Scar  
Genitals  
Edema  
Skin  
Decubitus  
**HEART Wt. 340**  
Pericardium  
Hypertrophy  
Dilation  
Muscle  
Valves  
Coronaries *widely patent*  
**AORTA**  
**VESSELS**  
**LUNGS Wt.**  
R *900*  
L *850*  
Adhesions  
Fluid  
Atelectasis  
✓ Oedema *marked*  
✓ Congestion  
Consolidation  
Bronchi  
Nodes  
**PHARYNX**  
**TRACHEA**  
**THYROID**  
**THYMUS**  
**LARYNX**  
**HYOID intact**  
**ABDOMINAL WALL FAT**

RV *0.2*  
Septum *1.1*  
LV *1.2*  
Septum

**PERITONEUM**

Fluid  
Adhesions  
**LIVER Wt. 1350**  
Capsule  
Lobules  
~~Fibros~~  
G B ✓  
~~Calculus~~  
Bile ducts  
**SPLEEN Wt. 115**  
Color  
Consistency  
Capsule  
Malpighment

**PANCREAS**

**ADRENALS**

**KIDNEYS Wt.**

R *150*  
L *140*  
Capsule  
Cortex *Small*  
Vessels  
Pelvis  
Ureters

**BLADDER ~ 10cc urine**

**GENITALIA**

Prostate ✓  
Testes ✓  
Uterus  
Tubes  
Ovaries

**OESOPHAGUS**

**STOMACH**

Contents *~ 325cc green yellow*

**DUOD. & SM. INT.**

*fluid w/ firm*

**APPENDIX ✓**

*chalky white*

**LARGE INT. ✓**

*particulate*

**ABDOM. NODES**

**SKELETON**

*non formed stool  
in sm + lrg.  
bowel*

Spine  
Marrow  
Rib Cage  
Long bones  
Pelvis

**SCALP**

**CALVARIUM**

**BRAIN Wt. 1510**

Dura  
Fluid  
Ventricles *congestion in*  
Vessels *mastoid air cells,*  
Middle ears *bilateral*  
Other

**PITUITARY**

**SPINAL CORD**

**TOXICOLOGY SPECIMENS**

**SECTIONS FOR HISTOPATHOLOGY**

**MICROBIOLOGY**

**DIAGRAMS  
X-RAYS**

**OTHER PROCEDURES**

**GROSS IMPRESSIONS**

Date <i>11-6-2022</i>	Time <i>0940</i>	Deputy Medical Examiner <i>B746</i>
--------------------------	---------------------	--

# MEDICAL REPORT

# 15

AUTOPSY CLASS:  A  B  C  Examination Only D

FAMILY OBJECTION TO AUTOPSY

Date: 11-6-22 Time: 0940 Dr. Hunt  
(Print)

FINAL ON: \_\_\_\_\_ By: Hunt  
(Print)

APPROXIMATE INTERVAL BETWEEN ONSET AND DEATH

2022-11542

CARTER, AARON CHARLES

ACC

334

DEATH WAS CAUSED BY: (Enter only one cause per line for A, B, C, and D)

### IMMEDIATE CAUSE:

(A) Drowning

Rapid

DUE TO, OR AS A CONSEQUENCE OF:

(B) Effects of difluoroethane and alprazolam

unknown

DUE TO, OR AS A CONSEQUENCE OF:

(C)

DUE TO, OR AS A CONSEQUENCE OF:

(D)

OTHER CONDITIONS CONTRIBUTING BUT NOT RELATED TO THE IMMEDIATE CAUSE OF DEATH:

Age: 34 Gender: Male / Female

### PRIOR EXAMINATION REVIEW BY DME

- BODY TAG  CLOTHING
- X-RAY (No. \_\_\_\_\_)  FLUORO
- SPECIAL PROCESSING TAG  MED. RECORDS
- AT SCENE PHOTOS (No. \_\_\_\_\_)

### CASE CIRCUMSTANCES

- EMBALMED
- DECOMPOSED
- >24 HRS IN HOSPITAL
- OTHER: \_\_\_\_\_ (Reason)

### TYPING SPECIMEN

TYPING SPECIMEN TAKEN BY: BH  
SOURCE: Heart blood

### TOXICOLOGY SPECIMEN

COLLECTED BY: BH  
 HEART BLOOD  STOMACH CONTENTS  
 FEMORAL BLOOD  VITREOUS

- TECHNIQUE:
- \_\_\_\_\_ BLOOD  SPLEEN
  - \_\_\_\_\_ BLOOD  KIDNEY
  - BILE  \_\_\_\_\_
  - LIVER  \_\_\_\_\_
  - URINE  \_\_\_\_\_

URINE GLUCOSE DIPSTICK RESULT: 4+ 3+ 2+ 1+ 0

TOX SPECIMEN RECONCILIATION BY: \_\_\_\_\_

### HISTOLOGY

Regular (No. \_\_\_\_\_)  Oversize (No. \_\_\_\_\_)  
Histopath Cut:  Autopsy  Lab

### TOXICOLOGY REQUESTS

FORM 3A:  YES  NO  
 NO TOXICOLOGY REQUESTED  
SCREEN  C  H  T  S  D  
 ALCOHOL ONLY  
 CARBON MONOXIDE  
 OTHER (Specify drug and tissue)  
Volatiles (Difluoroethane)

### REQUESTED MATERIAL ON PENDING CASES

- POLICE REPORT  MED HISTORY
- TOX FOR COD  HISTOLOGY
- TOX FOR R/O  INVESTIGATIONS
- MICROBIOLOGY  EYE PATH. CONS.
- RADIOLOGY CONS.
- CONSULT ON: \_\_\_\_\_
- BRAIN SUBMITTED
- NEURO CONSULT  DME TO CUT
- CRIMINALISTICS
- GSR  SEXUAL ASSAULT  OTHER

- NATURAL  SUICIDE  HOMICIDE
- ACCIDENT  COULD NOT BE DETERMINED

If other than natural causes,  
HOW DID INJURY OCCUR? Submerged in bathtub after inhalation of compressed gas and intake of alprazolam

WAS OPERATION PERFORMED FOR ANY CONDITION STATED ABOVE:  YES  NO

TYPE OF SURGERY: \_\_\_\_\_ DATE: \_\_\_\_\_

ORGAN PROCUREMENT  TECHNICIAN: M. Hernandez  
PREGNANCY IN LAST YEAR  YES  NO  UNK  NOT APPLICABLE

WITNESS TO AUTOPSY  EVIDENCE RECOVERED AT AUTOPSY  
Item Description: \_\_\_\_\_

RESIDENT

DME

BH



Department of Medical Examiner-Coroner, County of Los Angeles

## FORENSIC SCIENCE LABORATORIES

1104 North Mission Road, Los Angeles, CA 90033



## Laboratory Analysis Summary Report

Hunt, Brice M.D.Deputy Medical Examiner  
1104 North Mission Road  
Los Angeles, CA 90033 PendingTox**Coroner Case Number:** 2022-11542 **Decedent:** CARTER, AARON CHARLES

<u>SPECIMEN</u>	<u>SERVICE</u>	<u>DRUG</u>	<u>RESULT</u>	<u>ANALYST</u>
-----------------	----------------	-------------	---------------	----------------

**Alcohol Quantitation/Confirmation**

Blood, Heart

Alcohol-GC/FID-HS	Ethanol	Negative	A. Chavez
-------------------	---------	----------	-----------

**Drug Screen**

Blood, Heart

ELISA-Immunoassay	Benzodiazepines	PP	J. Posada
ELISA-Immunoassay	Cocaine and Metabolites	ND	J. Posada
ELISA-Immunoassay	Fentanyl	ND	J. Posada
ELISA-Immunoassay	Methamphetamine & MDMA	ND	J. Posada
ELISA-Immunoassay	Opiates: Codeine & Morphine	PP	J. Posada
ELISA-Immunoassay	Opiates: Hydrocodone & Hydromorphone	PP	J. Posada
ELISA-Immunoassay	Phencyclidine	ND	J. Posada

**Drug Screen/Confirmation**

Blood, Heart

Bases-GC/NPD &/or MS	Hydroxyzine	ND	A. Chavez
Bases-GC/NPD &/or MS	Norchlorcyclizine	0.24 ug/mL	A. Chavez
Bases-GC/NPD &/or MS	Quetiapine	ND	A. Chavez
Bases-GC/NPD &/or MS	Quetiapine Metabolite	Present	A. Chavez
Benzos (Free)-LC/MS/MS	Alprazolam	93 ng/mL	M. Liebl
Opiates-LC/MS/MS	Codeine, Free	ND	C. Castellino
Opiates-LC/MS/MS	Hydrocodone, Free	ND	C. Castellino
Opiates-LC/MS/MS	Hydromorphone, Free	ND	C. Castellino
Opiates-LC/MS/MS	Morphine, Free	ND	C. Castellino
Opiates-LC/MS/MS	Oxycodone, Free	ND	C. Castellino
Opiates-LC/MS/MS	Oxymorphone, Free	ND	C. Castellino
Vols-GC/FID-HS &/or MS	Difluoroethane	Present	A. Chavez

Coroner Case Number: 2022-11542 Decedent: CARTER, AARON CHARLES

<u>SPECIMEN</u>	<u>SERVICE</u>	<u>DRUG</u>	<u>RESULT</u>	<u>ANALYST</u>
-----------------	----------------	-------------	---------------	----------------

**Legend:**

		ND	Not Detected	SNS	Specimen Not Suitable
g	Grams	ng/g	Nanograms per Gram	TNP	Test Not Performed
g%	Gram Percent	ng/mL	Nanograms per Milliliter	ug	Micrograms
Inc.	Inconclusive	PP	Presumptive Positive	ug/g	Micrograms per Gram
mg	Milligrams	QNS	Quantity Not Sufficient	ug/mL	Micrograms per Milliliter

The alcohol analysis was performed in accordance to California Code of Regulations "Title 17" compliance by a qualified analyst in the Forensic Toxicology Laboratory, Forensic Laboratories Division, County of Los Angeles Department of Medical Examiner - Coroner.

Enzyme-linked immunosorbant assay (ELISA) provides only a preliminary analytical result that is contingent upon a confirmatory test. A "presumptive positive" (PP) signifies a detection of a drug class and must be confirmed by additional testing for true identification and/or quantitation of specific drug(s) present in the specimen.

Per the Department's Evidence Retention Policy, the blood specimen(s) will be retained for one year (minimum) and all other specimens six months (minimum) from Postmortem Exam.

Final Review By:



Sarah Buxton de Quintana  
Supervising Criminalist I

Date:

3/3/23

*The above results relate only to the items sampled and tested and have been technically and administratively reviewed and are the opinions and conclusions of the analysts noted. The final review has been certified by the noted Toxicologist to ensure that all standard operating procedures were followed as set by the Forensic Toxicology Laboratory, Forensic Sciences Laboratory Division, County of Los Angeles Department of Medical Examiner-Coroner.*



COUNTY OF LOS ANGELES

MEDICAL EVIDENCE

DEPARTMENT OF CORONER

**3A**

CASE # 2022-11542  
 DECEDENT'S NAME:  
**CARTER, AARON CHARLES**  
 DOD: 11/5/2022  
 INCOMING MODE:

Page 1 of 2

Drug Name	Rx Number	Date of Issue	Number Issued	Number Remaining	Form	Dosage	Rx Directions	Physician	Pharmacy Phone/Comments
ALPRAZOLAM	09576430734	8/16/2022	60	0	TABLET	2MG	1 2X DAILY	FABER, J	WALGREENS 6617225892
GABAPENTIN	08438680734	8/27/2021	150		CAPSULE	300MG	2 TWICE DAILY, 1 BED	FABER, J	WALGREENS 6617225892
GABAPENTIN	09576490734	8/16/2022	150		CAPSULE	300MG	2 TWICE DAILY, 1 BED	FABER, J	WALGREENS 6617225892
GABAPENTIN	08299490734	7/17/2021	150		CAPSULE	300MG	2 TWICE DAILY, 1 BED	FABER, J	WALGREENS 6617225892
GABAPENTIN	07950870734	3/30/2021	150		CAPSULE	300MG	2 TWICE DAILY, 1 BED	FABER, J	WALGREENS 6617225892
GABAPENTIN	08746400734	11/27/2021	150		CAPSULE	300MG	2 TWICE DAILY, 1 BED	FABER, J	WALGREENS 6617225892
GABAPENTIN	08949330734	1/25/2022	150		CAPSULE	300MG	2 TWICE DAILY, 1 BED	FABER, J	WALGREENS 6617225892
GABAPENTIN	09037230734	2/22/2022	150		CAPSULE	300MG	2 TWICE DAILY, 1 BED	FABER, J	WALGREENS 6617225892
HYDROXYZINE	08839660734	12/24/2021	60		TABLET	50MG	1 EVERY 12HRS	FABER, J	WALGREENS 6617225892

**Paraphernalia Description**

TABLET ORGANIZER W MULTIPLE PILLS. ALPRAZOLAM PRESCRIPTION MEDICATION BOTTLE FOR TAYLOR HELGESON/EMPTY.

**Investigator:**  
 MARLEEN NAVARRO (604249)

**Date:**  
 11/14/2022

COUNTY OF LOS ANGELES

MEDICAL EVIDENCE

DEPARTMENT OF CORONER

**3A**

CASE # 2022-11542  
 DECEDENT'S NAME:  
**CARTER, AARON CHARLES**  
 DOD: 11/5/2022  
 INCOMING MODE:

Page 2 of 2

Drug Name	Rx Number	Date of Issue	Number Issued	Number Remaining	Form	Dosage	Rx Directions	Physician	Pharmacy Phone/Comments
HYDROXYZINE	08949280734	1/25/2022	60	0	TABLET	50MG	1 EVERY 12 HRS	FABER, J	WALGREENS 6617225892
ONDANSETRON	1145090	6/9/2020	30		TABLET	4MG	1 DAILY	BERMANI, A	CVS 6617225784
PROPRANOLOL	08746350734	11/27/2021	90		TABLET	20MG	1 EVERY 8 HRS	FABER, J	WALGREENS 6617225892
QUETIAPINE	09376520734	6/12/2022	14		TABLET	50MG	1-2 AT BED	FABER, J	WALGREENS 6617225892 CONTAINING GABAPENTIN
QUETIAPINE	09669060734	9/15/2022	60	2	TABLET	50MG	1-2 AT BED	FABER, J	WALGREENS 6617225892
TRAZODONE	09576400734	8/16/2022	30	0	TABLET	50MG	1 EVERY NIGHT	FABER, J	WALGREENS 6617225892
<b>Paraphernalia Description</b> TABLET ORGANIZER W MULTIPLE PILLS. ALPRAZOLAM PRESCRIPTION MEDICATION BOTTLE FOR TAYLOR HELGESON/EMPTY.									
									<b>Investigator:</b> MARLEEN NAVARRRO (604249)
									<b>Date:</b> 11/14/2022




COUNTY OF LOS ANGELES

## CASE REPORT

DEPARTMENT OF CORONER

<b>1</b>	APPARENT MODE <b>ACCIDENT</b>										CASE NO <b>2022-11542</b>	
	SPECIAL CIRCUMSTANCES <b>Media Interest</b>										CRYPT <b>334</b>	
LAST, FIRST MIDDLE <b>CARTER, AARON CHARLES</b>										AKA <b>#</b>		
ADDRESS <b>42502 VALLEY VISTA DRIVE</b>										CITY <b>LANCASTER</b>	STATE <b>CA</b>	ZIP <b>93536</b>
SEX <b>MALE</b>	RACE APPEARS <b>CAUCASIAN</b>	DOB <b>12/7/1987</b>	AGE <b>34</b>	HGT <b>69 in.</b>	WGT <b>133 lbs.</b>	EYES <b>BROWN</b>	HAIR <b>BLOND</b>	TEETH <b>ALL NATURAL TEETH</b>	FACIAL HAIR <b>UNSHAVEN</b>	ID VIEW <b>Yes</b>	CONDITION <b>FAIR</b>	
MARK TYPE	MARK LOCATION	MARK DESCRIPTION										
TATTOO	CHEEKS	"LOVE" "PRINCE"										
TATTOO	RIGHT EYEBRO	BUTTERFLY										
TATTOO	LEFT FACE	FEMALE FACE										



[REDACTED]										
LA #	MAIN #	CII #	FBI #	MILITARY #	POB					
IDENTIFIED BY NAME (PRINT)			RELATIONSHIP	PHONE	DATE	TIME				
COMPARISON TO CALPHOTO					11/5/2022	17:00				
PLACE OF DEATH / PLACE FOUND		ADDRESS OR LOCATION			CITY	ZIP				
RESIDENCE		42502 VALLEY VISTA DRIVE			LANCASTER	93536				
PLACE OF INJURY	AT WORK	DATE	TIME	LOCATION OR ADDRESS		ZIP				
UNKNOWN	No			,,						
DOD	TIME	FOUND OR PRONOUNCED BY								
11/5/2022	11:14	LACFD ENG84, TRACEY								
OTHER AGENCY INV. OFFICER			PHONE	REPORT NO.	NOTIFIED BY	NO				
LASD LANCASTER - DEPUTY VANARSDALE #611			(661) 948-8466	022-19082-1159-496						
TRANSPORTED BY				TO	DATE	TIME				
DUSTIN MIRANDA				LOS ANGELES FSC	11/5/2022	21:12				
FINGERPRINTS?	Yes	CLOTHING	Yes	PA RPT	No	MORTUARY	TULIP CREMATIONS			
MED. EV.	Yes	INVEST. PHOTO #	86	SEAL TYPE	NOT SEALED	HOSP RPT	No			
PHYS. EV.	No	EVIDENCE LOG	Yes	PROPERTY?	Yes	HOSP CHART	No			
SUICIDE NOTE	No	GSR NO		RCPT. NO.	338731	PF NO.				
<p>SYNOPSIS</p> <p>THE DECEDENT IS A CELEBRITY WITH A KNOWN HISTORY OF SUBSTANCE ABUSE. THE DECEDENT HAD MULTIPLE INTERACTIONS WITH LOCAL POLICE RELATING TO THE SUBSTANCE ABUSE. THE DECEDENT WAS LAST KNOWN ALIVE ON 11/04/2022 AT ABOUT 0200 HOURS WHEN POLICE WERE CALLED FOR A WELFARE CHECK AFTER THE DECEDENT WAS REPORTEDLY SEEN/HEARD TO BE "HUFFING" ON THE SOCIAL MEDIA PLATFORM INSTAGRAM VIA A LIVE STREAM. DEPUTIES RESPONDED TO THE DECEDENT'S HOME AND MADE CONTACT WITH THE DECEDENT WHOM TOLD THEM TO LEAVE. ON 11/05 AT AROUND 1100 HOURS, THE DECEDENT'S "HOUSEKEEPER" KNOCKED ON HIS DOOR TO OFFER HIM COFFEE. WHEN SHE GOT NO RESPONSE AND AFTER HEARING THE DOGS BARKING, SHE LET HERSELF IN AND FOUND THE DECEDENT FULLY SUBMERGED IN THE BATHTUB. THE DECEDENT WAS REPORTEDLY IN THE FETAL POSITION BUT SUPINE (FACE UP) WITH HIS HANDS CURLED INTO HIS CHEST. THE JETS WERE ON IN THE BATHTUB. SHE CALLED 911 AND WAS INSTRUCTED TO PULL HIM OUT AND PERFORM CPR. DEATH WAS DETERMINED WITHOUT MEDICAL INTERVENTION BY PARAMEDICS AT THE SCENE. MULTIPLE CANS OF "SURF ONN" ELECTRONIC DUSTER WERE FOUND SCATTERED IN HIS BEDROOM AND BATHROOM. THE NOZZLE TIP TO ONE OF THE DUSTER CANS WAS FOUND IN THE FRONT POCKET OF A SWEATSHIRT FOUND NEAR THE BATHTUB. THE DECEDENT HAD A KNOWN HISTORY OF INHALENT ABUSE AND HAD RELAPSED AT SOME POINT THIS YEAR. THE DECEDENT WAS SUPPOSED TO CHECK IN WITH HIS OUTPATIENT DRUG COUNSELOR ON 11/04 AT 1800 HOURS BUT MISSED THE PHONE APPOINTMENT. THERE WAS NO OBVIOUS SUICIDE PARAPHERNALIA FOUND AT THE SCENE. THE DECEDENT'S FIANCEE AND HIS MOTHER BOTH STATED THE DECEDENT WAS NOT SUICIDAL AND MADE NO IDEATIONS PRIOR TO HIS DEATH. MULTIPLE BOTTLES OF PRESCRIPTION MEDICATION WERE FOUND THROUGHOUT HIS ROOM/BATHROOM AND WERE COLLECTED. THE BODY EXAM FOUND NO OBVIOUS EVIDENCE OF SUSPICIOUS TRAUMA; THERE IS NO SUSPICION OF FOUL PLAY AT THIS TIME. THE DECEDENT'S RIGOR MORTIS APPEARED TO BE 3-4; LIVIDITY BLANCHED WITH FIRM PRESSURE. THE DECEDENT WAS WEARING A T-SHIRT AND NECKLACE; HIS SWEATSHIRT, BEANIE, PANTS, AND SOCKS WERE SEEN ON THE FLOOR NEAR THE BATHTUB. THE BATHTUB WATER WAS GREEN AND HAD A FOUL ODOR.</p>										
MARLEEN NAVARRO				DATE	11/5/2022	REVIEWED BY	DATE	11/5/2022		
604249				TIME	20:22	AIMEE EARL	TIME	20:28		
[Signature]				INVESTIGATOR	[Signature]					

FORM #3 NARRATIVE TO FOLLOW?



**County of Los Angeles, Department of Coroner  
Investigator's Narrative**



Case Number: 2022-11542

Decedent: CARTER, AARON CHARLES

**Information Sources:**

Deputy B. Vanarsdale #611164: Los Angeles County Sheriff's Department Lancaster, 661-948-8466

Detectives Sanchez and Lugo: Los Angeles County Sheriff's Department Homicide Bureau, 323-890-5500

[REDACTED] Fiancée, [REDACTED]

[REDACTED] Mother, [REDACTED]

On scene investigation

**Investigation:**

This death was reported to our office on 11/05/2022 at 1216 hours as a first call.

I was assigned the call at 1640 hours by Investigator Benavidez-Parraz.

I arrived to the scene at 1651 hours and cleared the call at 1840 hours.

The decedent was transported to the Forensic Science Center by Forensic Attendant Miranda.

A routine manual search of the JDIC system using the decedent's name and date of birth found no record.

Criminalist callout criteria was reviewed and not met for this case.

**Location:**

Place of injury: Unknown, History of prescription medication abuse and inhalant abuse

Place of death: Residence, 42502 Valley Vista Drive, Lancaster, CA 93536

**Informant/Witness Statements:**

Deputy Vanarsdale and Detective Lugo and Sanchez gave me the following information: The only people in the residence at the time of this 911 call were the decedent and his "housekeeper". On 11/05/2022 around 1100 hours, the housekeeper knocked on the decedent's door to offer him coffee. The dogs were barking inside the room, but she got no response from the decedent. The housekeeper grew concerned and decided to open the door. The decedent's dogs ran towards the bathroom and the housekeeper found the decedent in the bathtub. 911 was called; the dispatcher told the housekeeper to pull the decedent out and perform CPR, which she reportedly did. Deputies from the Los Angeles County Lancaster station and paramedics from the Los Angeles County Fire Department engine 84 were dispatched to the scene. Death was determined without any medical intervention at 1114 hours by paramedic Tracey. According to the housekeeper, the jets in the bathtub were on. The decedent's feet were pointing north, and his head was pointing south. The fireplace in the bedroom was also on. Measurements of the bathtub were conducted by LASD FIS Roswell #451513. The bathtub measured about 2 ½ feet (width) by 5 feet (length). The depth was measured at about 13 inches. Several compressed air canisters were found throughout the decedent's bedroom and were collected by FIS Roswell. The decedent is known to local law enforcement due to multiple calls for service at this address. About a week prior, the decedent's fiancée had called requesting deputies conduct a welfare check on the decedent because she believed he was under the influence while driving his RV. Deputies made contact with the decedent; he was not arrested for driving under the influence. On 11/04 at around 0200 hours, deputies were dispatched to the residence for another welfare check after the decedent was believed to have been huffing on an Instagram live stream. The person who called it in thought he might have become unresponsive. Deputies from the LASD Lancaster station made contact with the decedent; the decedent was inside his home and yelled



County of Los Angeles, Department of Coroner  
Investigator's Narrative



Case Number: 2022-11542

Decedent: CARTER, AARON CHARLES

---

at them to get out from the stairs. Deputies left the residence. According to the decedent's housekeeper, this was the last time she saw him alive.

█ gave me the following information: She last had contact with the decedent on 11/03 at 1938 hours. She and the decedent were arguing via text. She left their residence on 10/31 around 1500 hours to spend time with their son. She usually returned home to the decedent after a few days, but lately she had been staying away because people were showing up to take photos of them. █ texted the decedent on 11/04 at 2310 hours but never got a response. The decedent was supposed to have a phone session with an outpatient drug counselor on 11/04 at 1800 hours but missed it without any explanation. The decedent had a history of Xanax abuse and inhalant abuse. They've been together three years; the decedent relapsed this year. There are no known suicide attempts and no suicidal ideations.

█ gave me the following information: She last spoke to the decedent by text on 11/03 at 1545 hours. The decedent wanted to go to rehab in Florida, but he couldn't leave California until 12/11 due to a court date/drug program commitment. She knew the decedent relapsed this year and said that █ called his sister about a month ago to tell her the decedent was huffing. There are no known suicide attempts or ideations.

### Scene Description:

The decedent's residence was scarcely furnished; most of the furniture was in the garage. The decedent's bedroom and music room appeared to be fully furnished. The decedent's bedroom was messy; the nightstands were dirty, and the drawers were in disarray. There were air canisters on the bed and in the bathroom. Multiple bottles of prescription medication were found in the drawers and an unlocked safe found in the bathroom. There was fecal matter in the closet. The water in the bathtub was green and there was grime around the edge of the tub.

The decedent was seen lying supine on the floor next to the bathtub. His feet were pointing northeast and his head was pointing northwest. There was grimy water on the floor underneath and around the decedent. There were two towels folded up on the floor between the bathtub and the decedent's body. The decedent's clothing (pants, sweatshirt, beanie) were found underneath the bathroom vanity near the decedent's feet.

The nozzle tip to one of the duster cans was found in the front pocket of the sweatshirt found on the floor near the decedent.

### Evidence:

I collected prescription medication; see evidence log.

### Body Examination:

The decedent is a male Caucasian adult with brown eyes, blond hair, an unshaven face, and apparent natural teeth. He was wearing a beige shirt. He had several tattoos, some of which were: "Prince" and "Love" on his cheeks, a butterfly above his right eyebrow, a female face on the left side of his face. There was a small abrasion on his left eyebrow and a small abrasion at the base of his septum. No obvious evidence of suspicious trauma was noted. Rigor mortis appeared to be 3-4 and resolving. Lividity blanched with firm pressure.

### Identification:

The decedent was positively identified by visual comparison to his California driver's license, █ as Aaron Charles Carter, date of birth: 12/07/1987.



County of Los Angeles, Department of Coroner  
Investigator's Narrative



Case Number: 2022-11542

Decedent: CARTER, AARON CHARLES

---

**Next of Kin Notification:**

I spoke to the decedent's mother [REDACTED] and she confirmed the decedent was not married and has a minor child.

**Tissue Donation:**

The decedent is not a viable candidate due to the condition of his body.

**Autopsy Notification:**

No autopsy requests.

A handwritten signature in black ink, appearing to read "Marleen Navarro".

MARLEEN NAVARRO

11/21/2022

Date of Report

A handwritten signature in black ink, appearing to read "Kelswell".

SUPERVISOR

AUTOPSYFILES.ORG